

Adaptation process of the skin graft to vaginal mucosa after McIndoe vaginoplasty

M. Bekerecioglu · O. Balat · M. Tercan · M. Karakok ·
M. G. Ugur · D. Isik

Received: 8 November 2006 / Accepted: 30 May 2007 / Published online: 4 March 2008
© Springer-Verlag 2008

Abstract

Objective There are many methods of treatment of vaginal agenesis.

Methods In this study, patients who underwent McIndoe vaginoplasty were evaluated for development of vaginal mucosa. Vaginal pH measurements, smears, and punch biopsies were obtained from seven patients postoperatively at 3, 6, and 12 months after having McIndoe vaginoplasty.

Results Neovaginal smears indicated no specific data for mucosal development at the 3rd and 6th month after the operation. However, Doderlein bacilli were determined at

the 12th month. Histopathological examination of punch biopsies revealed dermal and subdermal thickening at the 3rd month, partial adaptation to mucosa at 6th month, and full adaptation to mucosa at 12th month. Also normal vaginal pH levels were recorded at the 12th month.

Conclusion As a result of the adaptation process, the split thickness skin graft acquired both histological and physiological characteristics of normal vaginal mucosa. Also, neovaginal epithelium was evaluated to be macroscopically similar to normal vaginal mucosa, 12 months after the operation.

Keywords Vaginoplasty · Skin graft · Vaginal mucosa

M. Bekerecioglu
Faculty of Medicine, Department of Plastic
Reconstructive and Aesthetic Surgery,
Gaziantep University, Gaziantep, Turkey

O. Balat
Faculty of Medicine,
Department of Obstetrics and Gynecology,
Gaziantep University, Gaziantep, Turkey

M. Tercan
Department of Plastic Surgery,
Haydarpasa Training Hospital, Istanbul, Turkey

M. Karakok
Faculty of Medicine, Department of Pathology,
Gaziantep University, Gaziantep, Turkey

M. G. Ugur
Department of Obstetrics and Gynecology,
Kahramanmaraş Pazarcik Government Hospital,
Kahramanmaraş, Turkey

D. Isik (✉)
Department of Plastic Reconstructive and Aesthetic Surgery,
Gaziantep Avukat Cengiz Gokcek Government Hospital,
Gaziantep, Turkey
e-mail: daghanmd@yahoo.co.uk

Introduction

Müllerian agenesis disorders include congenital absence of the vagina and uterus. Estimates of the incidence of congenital absence of vagina vary from 1:4,000 to 10,000 [1–3]. Although many treatment methods are described in related literature, skin graft procedures are the most commonly used techniques. Split thickness skin graft (STSG) technique for the vagina was first described by Abbé in 1898, but is more commonly known as the McIndoe operation [2]. The vagina is a pliable, viscous, hollow organ, whose shape is determined by the surrounding structures and by its attachment to the pelvic wall. The vaginal wall is made up of the same layers as all hollow viscera (i.e. mucosa, submucosa, muscularis, and adventitia) [1]. Vaginal mucosa has a lining epithelium of a non-keratinized, stratified squamous type that lies on a dense dermis-like submucosa. STSG contains the epidermis and a portion of dermis. The aim of this study is to evaluate the adaptation process of the skin graft to vaginal mucosa in patients with vaginal agenesis who underwent McIndoe vaginoplasty.

Materials and methods

Seven patients with congenital absence of the vagina underwent McIndoe vaginoplasty, as previously published by Tercan et al. [4]. All of the patients were examined, and a vaginal pH measurement, smear, and punch biopsy were obtained postoperatively at 3, 6, and 12 months. At the time of the vaginal pH measurement, smear, and punch biopsy procedures, there was no sign of infection to be found in any of the patients. The punch biopsy specimens were obtained with a 4 mm biopsy punch from vaginal apex and lateral vaginal walls, under local anesthesia. Because of the anatomical proximity of urethra, bladder, and rectum to the vaginal lumen, the punch biopsies were not taken from the anterior and posterior walls. The donor areas of punch biopsies were left for secondary healing. Neovaginal smears were stained by the Pap-smear technique. Histopathological examinations of punch biopsies were performed routinely with hematoxylin and eosin staining. Vaginal swabs were rolled onto pH indicator papers for vaginal pH assessment.

Results

The mean age of patients was 21.5 years (17–29). After a follow-up period of 12 months, the mean length and diameter of the neovaginas was 8.7 and 2.6 cm, respectively. The neovaginal epithelium was macroscopically similar to normal vaginal mucosa. Post-operative sexual behavior inquiry revealed sexual desire and pleasure (100%) with artificial lubrication. All patients were completely satisfied with the results of their operation. Vaginal smears at the third and sixth months revealed that mucosa of the neovagina contained variable amounts of keratinized material. Eosinophilic cells and Doderlein bacilli were observed in the neovaginal epithelium at the 12th month (Table 1). The histopathological examination of biopsies revealed dermal and subdermal thickening without any sign of vaginal mucosa development at the 3rd month. Partial adaptation to vaginal mucosa was observed at 6th month (Fig. 1). Full adaptation of skin grafts to vaginal mucosa was confirmed at the 12th month (Fig. 2). Vaginal pH measurements were normal (mean 4.35) at the 12th month, but abnormal pH levels

Table 1 Parameters of the neovagina in the follow-up period

Parameters	Time		
	3rd month	6th month	12th month
Smear	–	–	+
Normal pH	–	–	+
Biopsy	–	±	+

–: Negative findings, ±: partially adaptation, +: positive findings

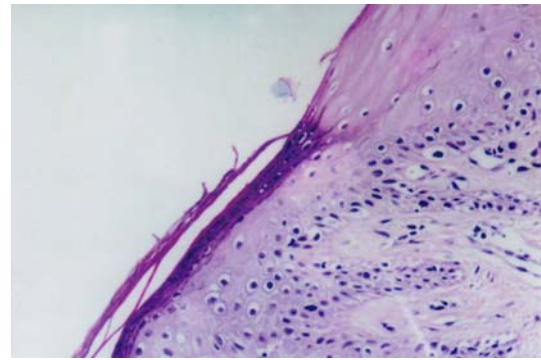


Fig. 1 Close-up view of adaptation to vaginal mucosa at 6th month postoperatively. Zone of unkeratinized squamous epithelium that is rich in glycogen. H&E \times 200

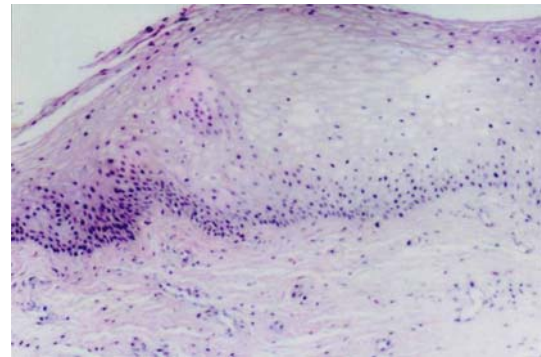


Fig. 2 Absence of hyperkeratosis and full adaptation to mucosa at 12th month postoperatively. Squamous epithelium that is rich in glycogen. H&E \times 100

were measured at the 3rd (mean 6.5) and 6th (mean 5.5) months (Table 2).

Discussion

Congenital absence of the uterus and the vagina, known as the Mayer-Rokitansky-Küster-Hauser syndrome, is the most common clinical example of the anomaly [5]. The etiology of vaginal agenesis is unknown. Such young girls have a normal pattern of chromosomes (46, XX) and normal external genitalia [1, 5]. Sexual inability along with infertility may result in severe psychological problems. Many techniques have been proposed for the treatment of vaginal agenesis such as dilatation without surgery, labial flaps, musculocutaneous flaps, intestinal flaps, free flaps, skin grafting, scalp grafting, oral mucosa grafting, amnion membrane grafting, graft with tissue expansion, and graft with vacuum-assisted closure, etc. [1–4, 6–13]. Recently, it was reported that vaginal epithelial and smooth muscle cells were cultured and expanded in vitro. They stated that the resulting tissue was phenotypic and had functional properties similar to normal vaginal tissues [14].

Table 2 Vaginal pH levels

Patients	Age (years)	Vaginal pH levels		
		3rd month	6th month	12th month
1	22	6.5	5.5	4.5
2	24	6.0	5.5	4.5
3	17	6.5	5.0	4.0
4	29	7.0	6.0	4.5
5	21	6.0	5.5	4.5
6	18	7.0	5.5	4.5
7	20	6.5	5.5	4.0

All methods begin with the dissection of a new vaginal pocket between the rectum and the bladder. In the McIndoe technique, this space is resurfaced with STSGs. STSGs serve well as replacements for the mucosa of the vagina. Skin grafts used for mucosa replacement become adapted with some alterations in their characteristics but they do not undergo a complete metaplasia to become mucosa, but a pseudomucosal metaplasia that makes the wall's consistency as similar as possible to a real vaginal mucous membrane, since the skin is too highly differentiated [15].

It is reported that it takes months or sometimes years after skin grafting until the skin graft loses all of its skin properties, and adapts to its new environment, finally becoming a mucosa [16–18]. We suggest that the partially anaerobic and wet milieu of the neovagina, in combination with the effect of estrogen mediated cyclic changes may have resulted in the adaptation process of skin graft to become vaginal mucosa. But, the duration of adaptation process is not stated exactly. In this study, the duration of adaptation process was determined. Neovaginal smears indicated no specific data of mucosal development at the 3rd and 6th months, but, Doderlein bacilli were determined at the 12th month. The presence of Doderlein bacilli suggests that the regional environment of the artificial vagina was almost the same as that of the normal vagina [19]. Histopathological examination of punch biopsies revealed dermal and subdermal thickening at the 3rd month, partial adaptation to mucosa at the 6th month, and full adaptation to mucosa at the 12th month. As a result of the adaptation process, the split thickness skin graft acquires both histological and physiological characteristics of normal vaginal mucosa. Also, neovaginal epithelium was evaluated to be macroscopically similar to normal vaginal mucosa at the 12th month after the operation.

Production of lubrication usually takes longer in the neovagina [20]. We observed that lubrication of the neovagina started at the 6th month, and it was almost normal at the 12th month. But the patients sometimes needed artificial

lubrication for sexual pleasure. Pierce et al. [21] demonstrated the conversion of skin to the vaginal epithelium after 20 years that included normal vaginal pH levels, normal vaginal epithelial glycogen levels, and complete loss of hair, pigment, and sweat glands. Normal vaginal pH levels (4.35) were determined at 12th month, postoperatively, but abnormal vaginal pH levels were determined at the 3rd (6.5) and 6th (5.5) months. The vaginal flora of a healthy woman is composed of Doderlein bacilli (different species of lactobacilli) forming a biofilm on the mucosa [22]. Doderlein bacilli were showed at 12th month in a study, and it is reported that the total bacteria count was lower in neovagina than healthy sigmoid colons after construction of a neovagina using the sigmoid colon [13].

Unfortunately, neovaginal carcinomas were reported [1, 23, 24]. We have not found any malignancy in histopathological examinations (smears and punch biopsies) during the follow-up period.

Epithelium of the skin transplanted to the vagina can undertake the oncogenic potential of the reproductive tract. Therefore, follow-up examinations should be performed indefinitely after vaginal reconstruction.

Study of the full thickness skin graft (FTSG) technique for treatment of patients with vaginal agenesis is ongoing in our clinic. Follow-up examinations for the adaptation process of FTSG to vaginal mucosa are in progress.

References

1. Rock JA (1997) Surgery for anomalies of the mullerian ducts. In: Rock JA, Thompson JD (eds) Te Linde's operative gynecology. 8th edn. Lippincott-Raven Publishers, Philadelphia, pp 687
2. Sadove RC, Horton CE (1988) Utilizing full-thickness skin grafts for vaginal reconstruction. *Clin Plast Surg* 15:443–448
3. Hockel M, Menke H, Germann G (2003) Vaginoplasty with split skin grafts from the scalp: optimization of the surgical treatment for vaginal agenesis. *Am J Obstet Gynecol* 188:1100–2
4. Tercan M, Balat O, Bekerecioglu M, Atik B (2002) The use of fibrin glue in the McIndoe technique of vaginoplasty. *Plast Reconstr Surg* 109:706–709
5. Folch M, Pigem I, Konje JC (2000) Mullerian agenesis: etiology, diagnosis, and management. *Obstet Gynecol Surv* 55:644–649
6. Simman R, Jackson IT, Andrus L (2002) Prefabricated buccal mucosa-lined flap in an animal model that could be used for vaginal reconstruction. *Plast Reconstr Surg* 109:1044–1049
7. Karim RB, Hage JJ, Dekker JJ, Schoot CM (1995) Evolution of the methods of neovaginoplasty for vaginal aplasia. *Eur J Obstet Gynecol Reprod Biol* 58:19–27
8. Hockel M, Menke H, Germann G (2003) Vaginoplasty with split skin grafts from the scalp: optimization of the surgical treatment for vaginal agenesis. *Am J Obstet Gynecol* 188:1100–1102
9. Johnson N, Batchelor A, Lilford RJ (1991) Experience with tissue expansion vaginoplasty. *Br J Obstet Gynaecol* 98:564–568
10. Johnson N, Lilford RJ, Batchelor A (1991) The free-flap vaginoplasty; a new surgical procedure for the treatment of vaginal agenesis. *Br J Obstet Gynaecol* 98:184–188
11. Yesim OG, Ozcan M (2003) Neovaginal construction with buccal mucosal grafts. *Plast Reconstr Surg* 111:2250–2254

12. Hallberg H, Holmstrom H (2003) Vaginal construction with skin grafts and vacuum-assisted closure. *Scand J Plast Reconstr Surg Hand Surg* 37:97–101
13. Toolenaar TA, Freundt I, Wagenvoort JH, Huikeshoven FJ, Vogel M, Jeekel H, Drogendijk AC (1993) Bacterial flora of the sigmoid neovagina. *J Clin Microbiol* 31:3314–3316
14. De Filippo RE, Yoo JJ, Atala A (2003) Engineering of vaginal tissue in vivo. *Tissue Eng* 9:301–306
15. Seccia A, Salgarello M, Sturla M, Loreti A, Latorre S, Farallo E (2002) Neovaginal reconstruction with the modified McIndoe technique: a review of 32 cases. *Ann Plast Surg* 49:379–384
16. Lelle RJ, Heidrenreich W, Schneider J (1990) Cytologic findings after construction of a neovagina using two surgical procedures. *Surg Gynecol Obstet* 170:21–24
17. Alessandrescu D, Peltecu GC, Buhimschi CS, Buhimschi IA (1996) Neocolpopoiesis with split-thickness skin graft as a surgical treatment of vaginal agenesis: retrospective review of 201 cases. *Am J Obstet Gynecol* 175:131–138
18. Belleannee G, Brun JL, Trouette H, Mompart JP, Goussot JF, Brun G (1998) Cytologic findings in a neovagina created with Vecchi-etti's technique for treating vaginal aplasia. *Acta Cytol* 42:945–948
19. Takashina T, Takashina T, Kanda Y, Tsumura N, Hayakawa O, Tanaka S, Ito E (1988) Postoperative changes in vaginal smears after vaginal reconstruction with a free skin graft. *Acta Cytol* 32:109–112
20. Masters WH, Johnson VW (1961) The artificial vagina: anatomic, physiologic, psychosexual function. *West J Surg* 69:192–212
21. Pierce GW, Klabunde EH, O'connor GB, Long AH (1956) Changes in skin flap of a constructed vagina due to environment. *Am J Surg* 92:4–8
22. Lepargneur JP, Rousseau V (2002) Protective role of the Doderlein flora. *J Gynecol Obstet Biol Reprod* 31:485–494
23. Gallup DG, Castle CA, Stock RJ (1987) Recurrent carcinoma in situ of the vagina following split thickness skin graft vaginoplasty. *Gynecol Oncol* 26:98–102
24. Steiner E, Woernle F, Kuhn W, Beckmann K, Schmidt M, Pilch H, Knapstein PG (2002) Carcinoma of the neovagina: case report and review of the literature. *Gynecol Oncol* 84:171–175